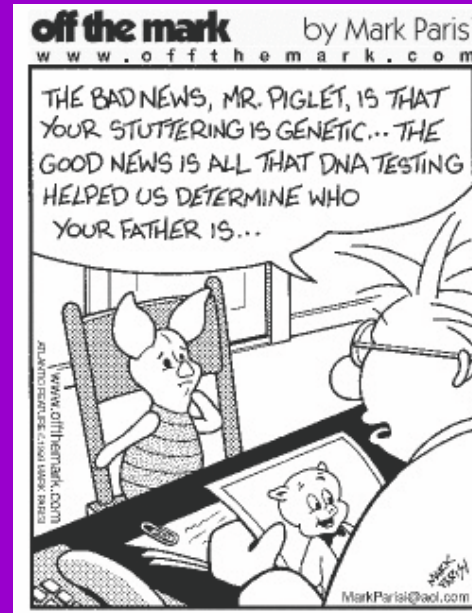


TACATGAGGTTCCGCTAGACTAGCTACTCACTAGCTATGTCTCGGTYACGATCTATACGGCGGAGCTAGGCCATTATCTATCTTACTTCGAGCTATGGACTTCAGAAGAAGCTCAGACTAGCACGCTTATATTTTTTTTTTT



April, 2006

Angela Scheuerle, M.D.

Procedures

What they tell you
and
What they don't

Angela Scheuerle, M.D.
Tesserae Genetics

Think outside the box

TACATGAGGTTCCGCTAGACTAGCTACTCACTAGCTATGTCTCGGTYACGATCTATACGCCGGAGCTAGGCCTTATCTATCTTACTTCGAGCTATGGACTTCAGAAGAAGCTCAGACTAGCACGCTTATATTTTTTTTTT

RED	GREEN	BLUE	YELLOW	PINK
ORANGE	BLUE	GREEN	BLUE	WHITE
GREEN	YELLOW	ORANGE	BLUE	WHITE
BROWN	RED	BLUE	YELLOW	GREEN
PINK	YELLOW	GREEN	BLUE	RED

The Stroop Effect

Advertising tricks

TACATGAGGTTCCGCTAGACTAGCTACTCACTAGCTATGTCTCGGTYACGATCTATACGCGGAGCTAGGCCTTATCTATCTTACTTCGAGCTATGGACTTCAGAAGAAGCTCAGACTAGCACGCTTATATTTTTTTTTT



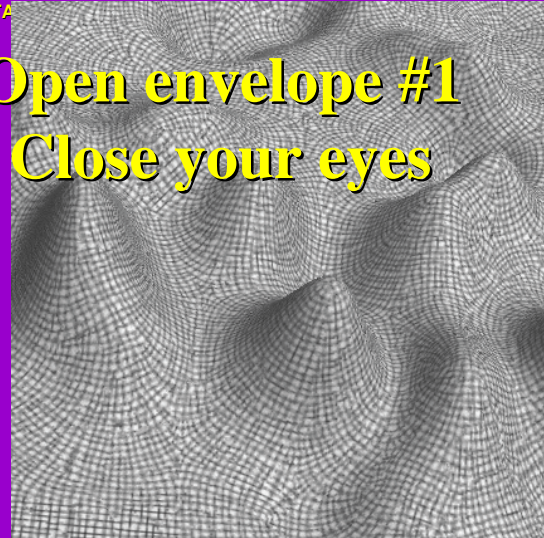

April, 2006

Angela Scheuerle, M.D.

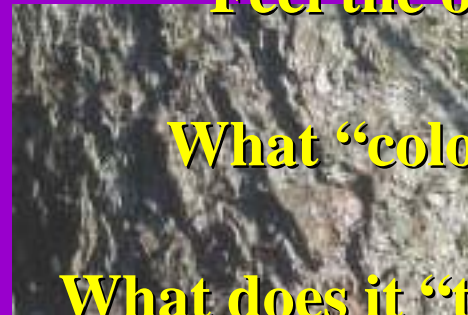
TACATGAGGTTCCGCTAGACTAGCTACTCACTAGCTATGTCTCGGTYACGATCTATA

TCAGAAGAAGTTCAGACTAGCAGGCTTATATTTTTTTTTTT

Open envelope #1
Close your eyes



Feel the object



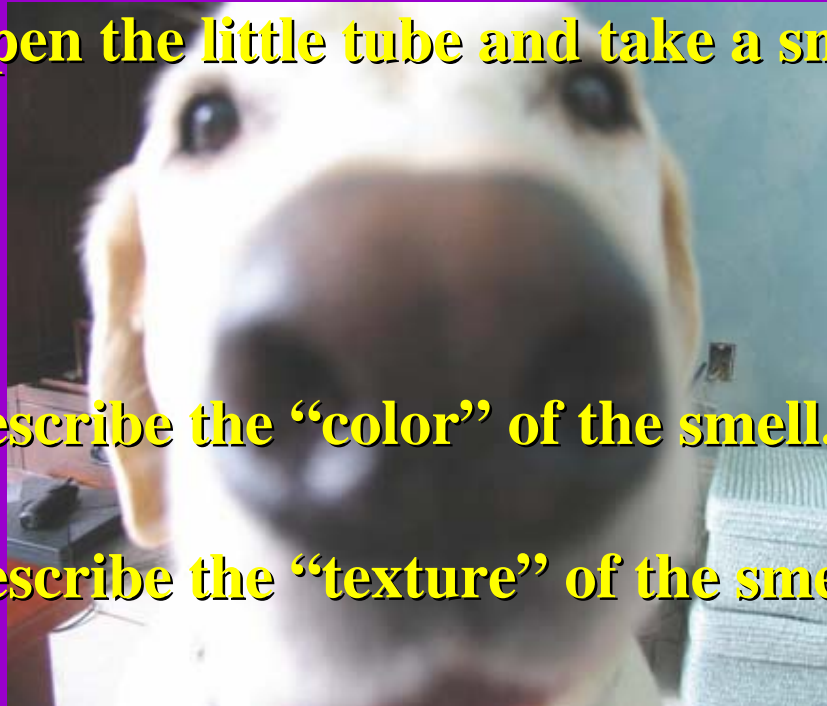
What "color" is it



What does it "taste" like?

TACATGAGGTTCCGCTAGACTAGCTACTCACTAGCTATGTCTCGGTYACGATCTATACGCCGGAGCTAGGCCTTATCTATCTTACTTCGAGCTATGGACTTCAGAAGAAGCTCAGACTAGCACGCTTATATTTTTTTTTT

Open the little tube and take a sniff.



Describe the “color” of the smell.

Describe the “texture” of the smell.

What does it “sound” like?



Concepts

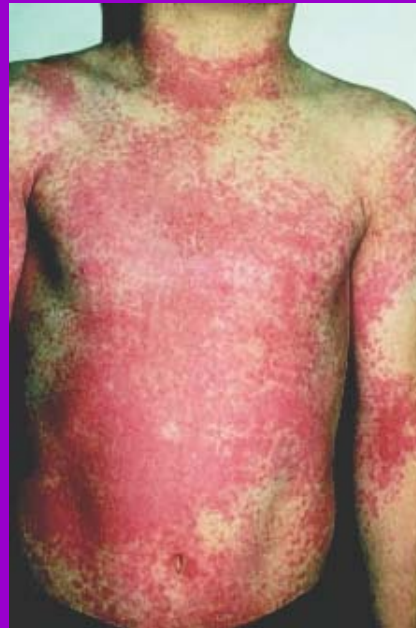TACATGAGGTTCCGCTAGACTAGCTACTCACTAGCTATGTCTCGGTYACGATCTATACGCCGGAGCTAGGCCTTATCTATCTTACTTCGAGCTATGGACTTCAGAAGAAGCTCAGACTAGCACGCTTATATTTTTTTTTT

- **Physical Exam**
 - **Inspection**
 - What do you see?
 - **Auscultation**
 - What do you hear?
 - **Palpation**
 - What do you feel?

Rash

TACATGAGGTTCCGCTAGACTAGCTACTCACTAGCTATGTCTCGGTYACGATCTATACGCGGAGCTAGGCCTTATCTATCTTACTTCGAGCTATGGACTTCAGAAGAAGCTCAGACTAGCACGCTTATATTTTTTTTTT

Inspection



Auscultation



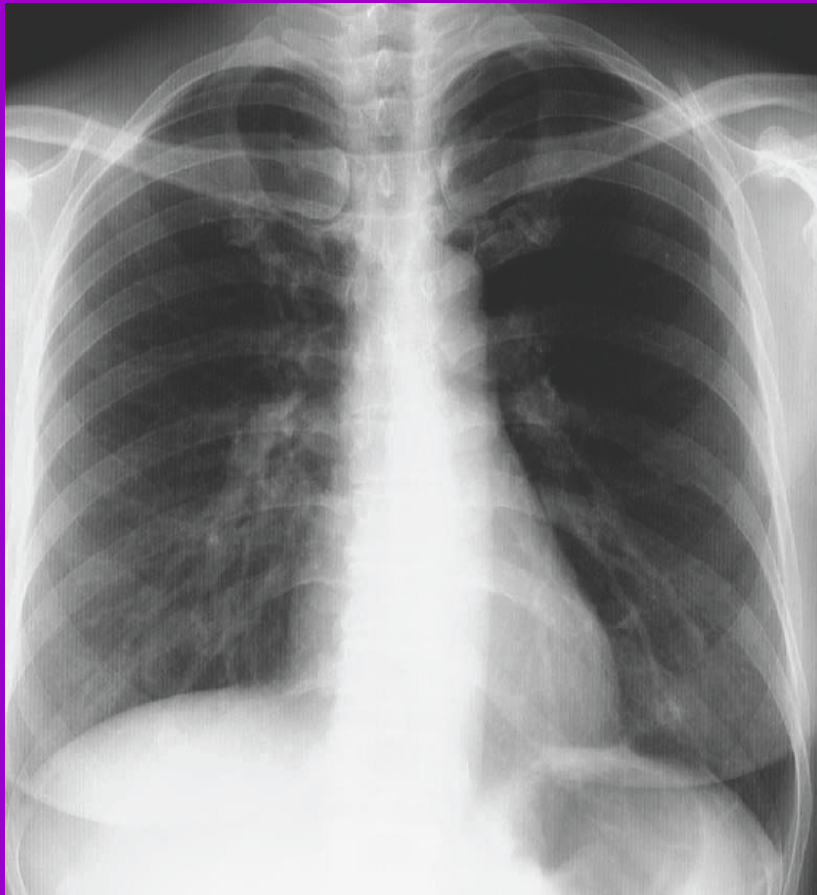Palpation

Open Envelope #2

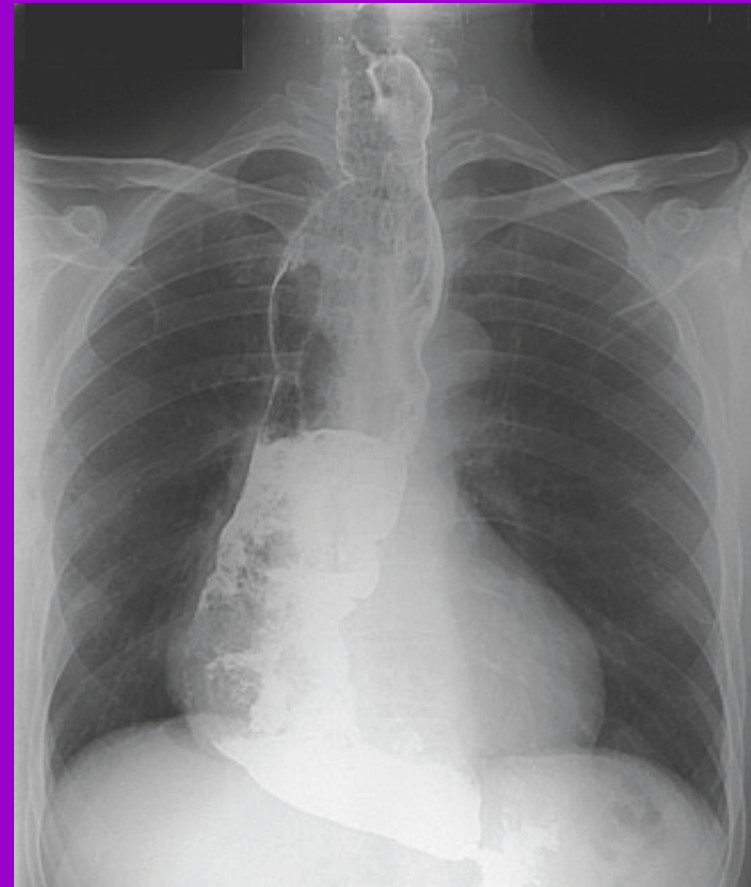
What does the rash feel like?

Xrays

TACATGAGGTTCCGCTAGACTAGCTACTCACTAGCTATGTCTCGGTYACGATCTATACGCCGGAGCTAGGCCTTATCTATCTTACTTCGAGCTATGGACTTCAGAAGAAGCTCAGACTAGCACGCTTATATTTTTTTTTT



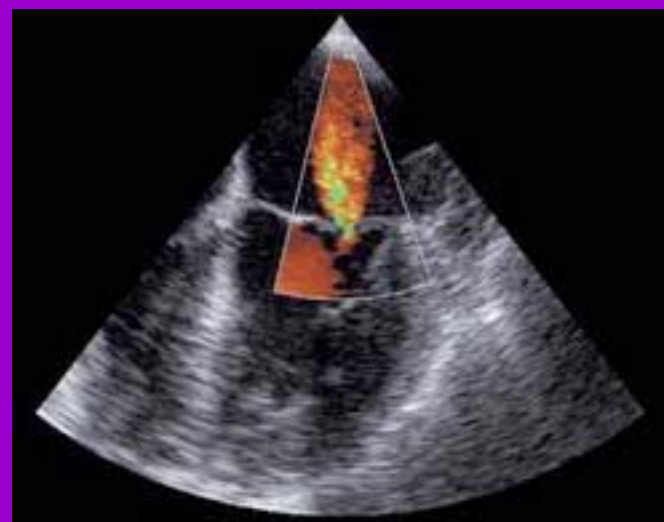
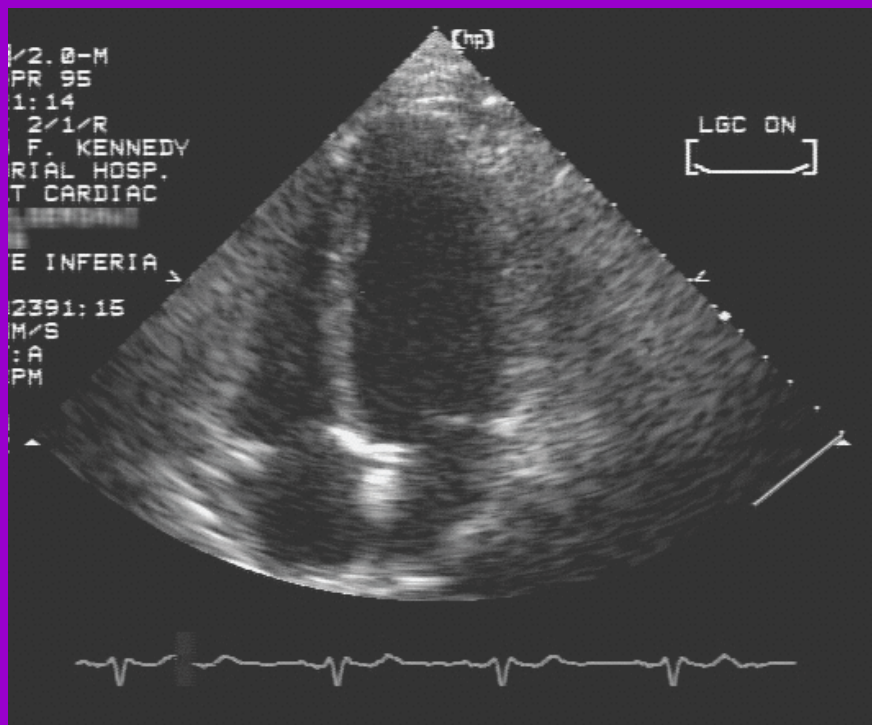
April, 2006



Angela Scheuerle, M.D.

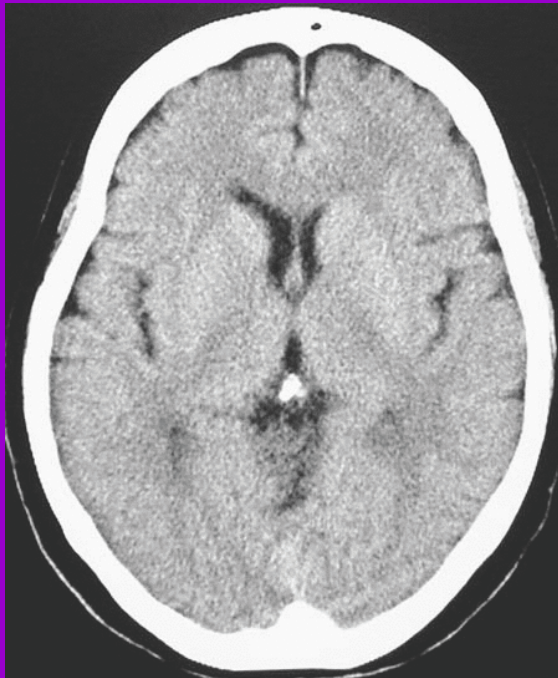
Ultrasound

TACATGAGGTTCCGCTAGACTAGCTACTCACTAGCTATGTCTCGGTYACGATCTATACGCGGAGCTAGGCCCTTATCTATCTTACTTCGAGCTATGGACTTCAGAAGAAGCTCAGACTAGCACGCTTATATTTTTTTTTT

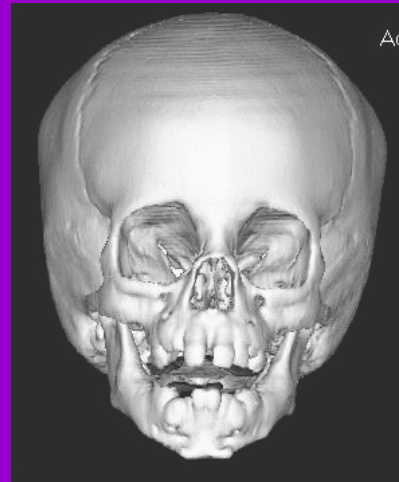


Computed Tomography (CT)

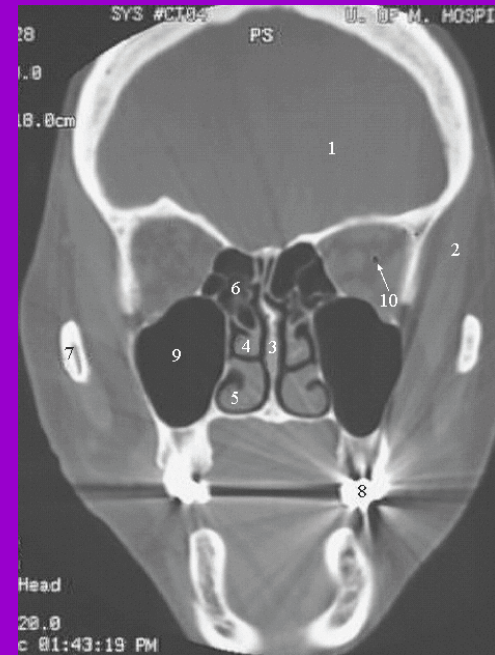
TACATGAGGTTCCGCTAGACTAGCTACTCACTAGCTATGTCTCGGTYACGATCTATACGCCGGAGCTAGGCCTTATCTATCTTACTTCGAGCTATGGACTTCAGAAGAAGCTCAGACTAGCACGCTTATATTTTTTTTTT



Cross-section



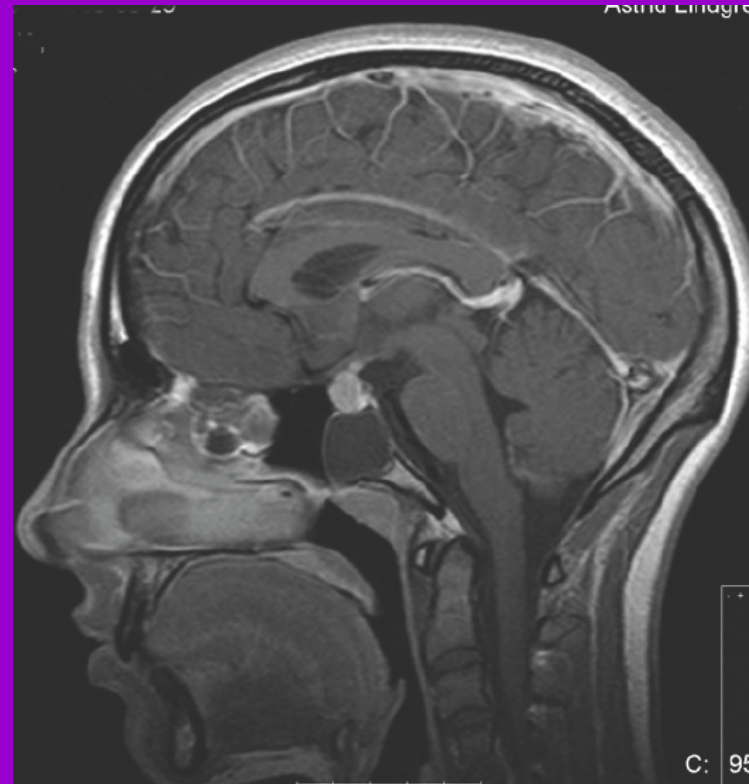
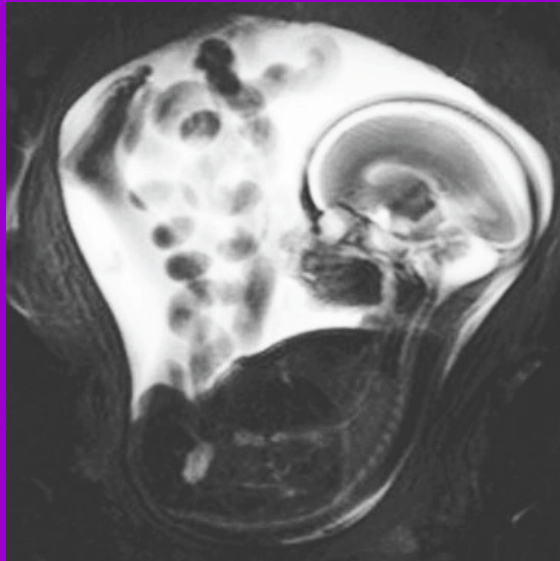
3-D



Coronal

Magnetic Resonance Imaging

TACATGAGGTTCCGCTAGACTAGCTACTCACTAGCTATGTCTCGGTYACGATCTATACGCCGGAGCTAGGCCCTTATCTATCTTACTTCGAGCTATGGACTTCAGAAGAAGCTCAGACTAGCACGCTTATATTTTTTTTTT



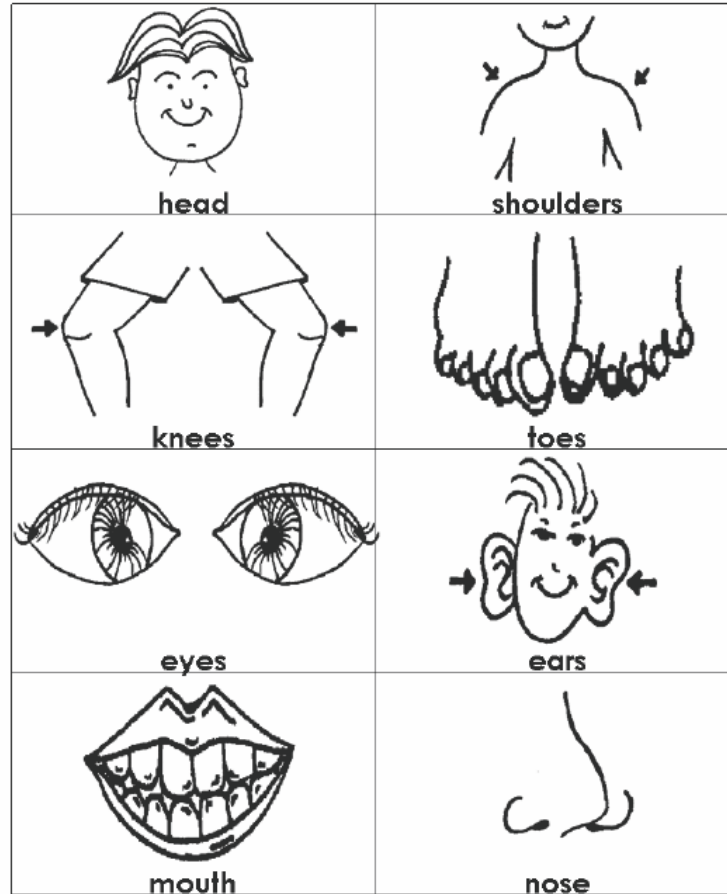
April, 2006

Angela Scheuerle, M.D.

Head, Shoulders, Knees and Toes

TACATGAGGTTCCGCTAGACTAGCTACTCACTAGCTATG

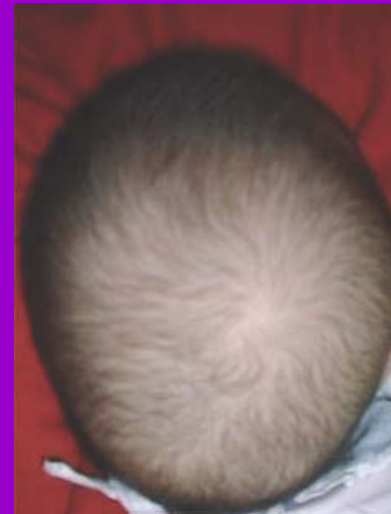GAACTCAGACTAGCACGCTTATATTTTTTTTTTT



Head

TACATGAGGTTCCGCTAGACTAGCTACTCACTAGCTATGTCTCGGTACGATCTATACGCCGGAGCTAGGCCTTATCTATCTTACTTCGAGCTATGGACTTCAGAAGAAGCTCAGACTAGCACGCTTATATTTTTTTTTT

Physical Exam



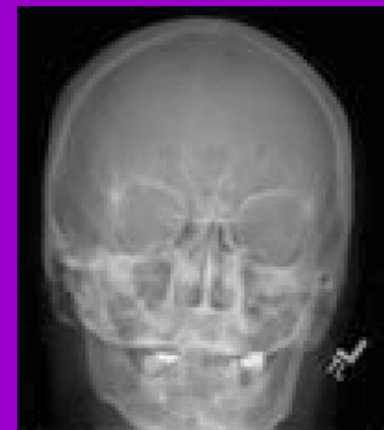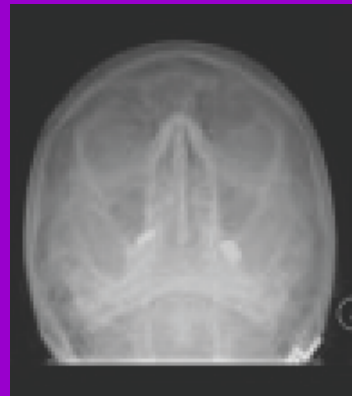
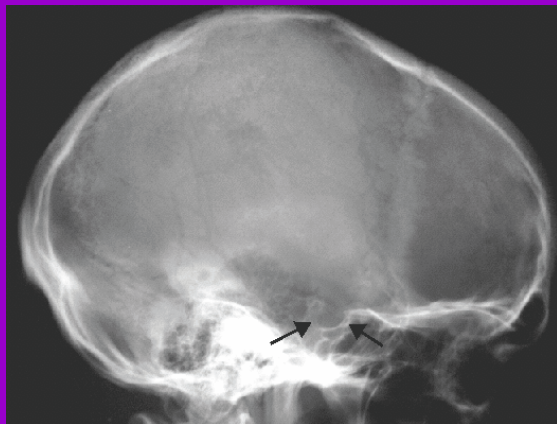
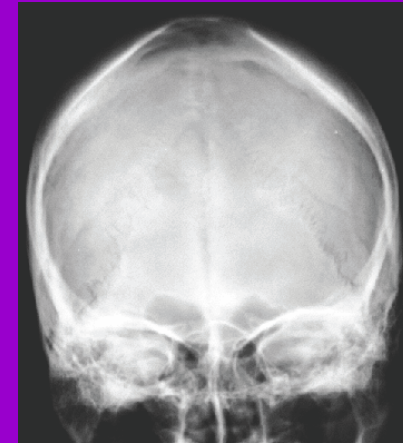
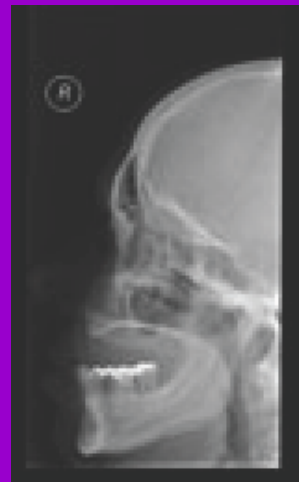
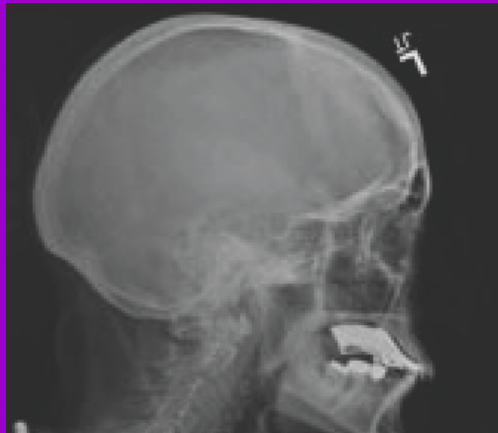April, 2006

Angela Scheuerle, M.D.

Head

TACATGAGGTTCCGCTAGACTAGCTACTCACTAGCTATGTCTCGGTYACGATCTATACGCCGAGCTAGGCCTTATCTATCTTACTTCGAGCTATGGACTTCAGAAGAAGCTCAGACTAGCACGCTTATATTTTTTTTTT

Xray



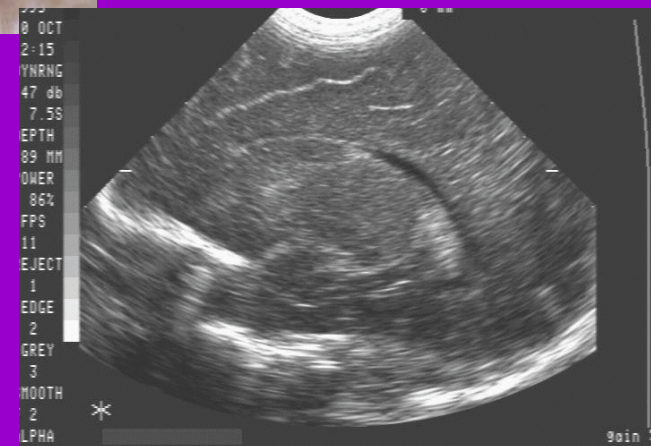
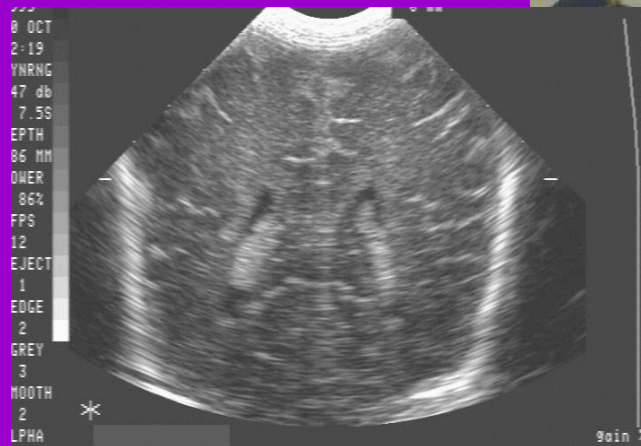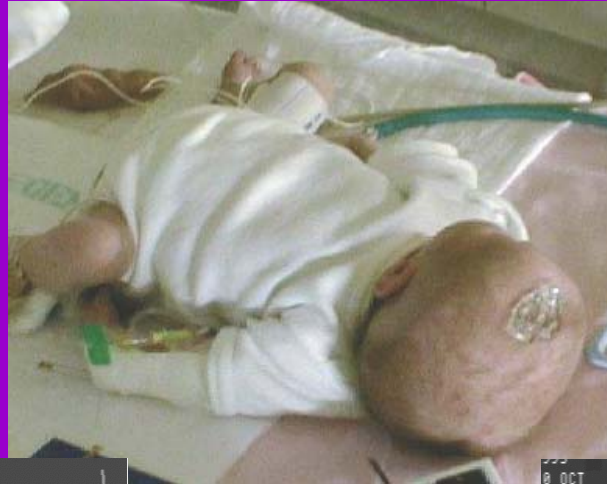April, 2006

Angela Scheuerle, M.D.

Head

TACATGAGGTTCCGCTAGACTAGCTACTCACTAGCTATGTCTCGGTYACGATCTATACGCCGAGCTAGGCCTTATCTATCTTACTTCGAGCTATGGACTTCAGAAGAAGCTCAGACTAGCACGCTTATATTTTTTTTTT

Ultrasound




April, 2006

Angela Scheuerle, M.D.

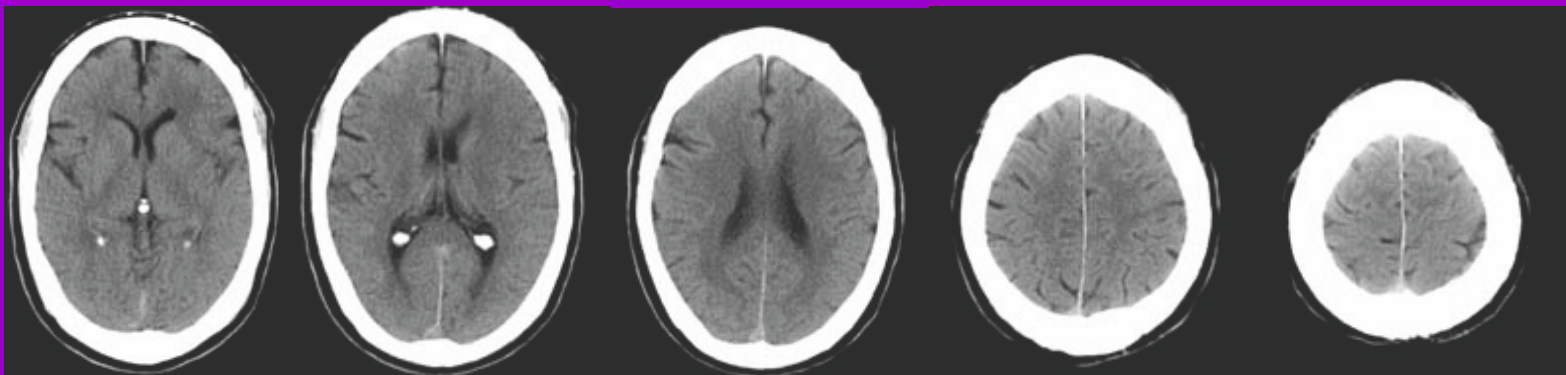
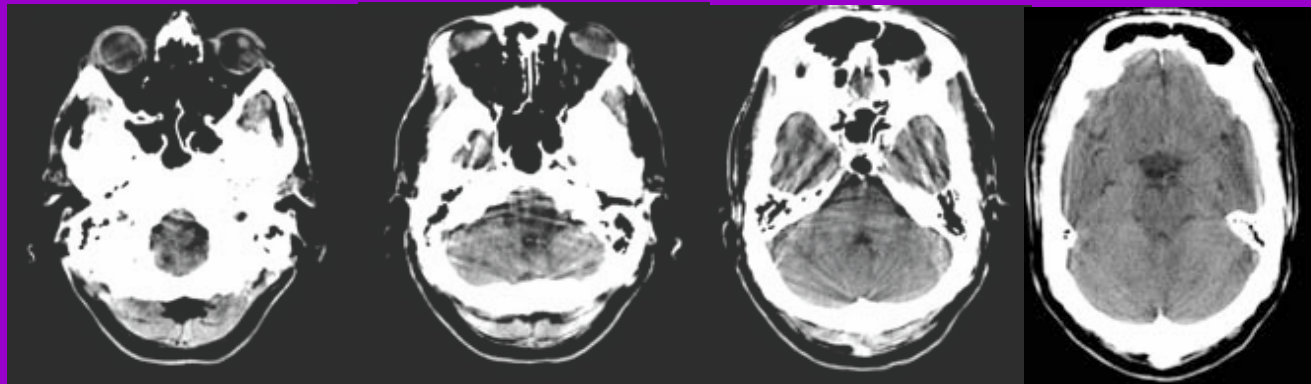
Head

TACATGAGGTTCCGCTAGACTAGCTACTCACTAGCTATGTCTCGGTYACGATCTATACGCCGGAGCTAGGCCTTATCTATCTTACTTCGAGCTA

ATATTTTTTTTTT



CT and MRI



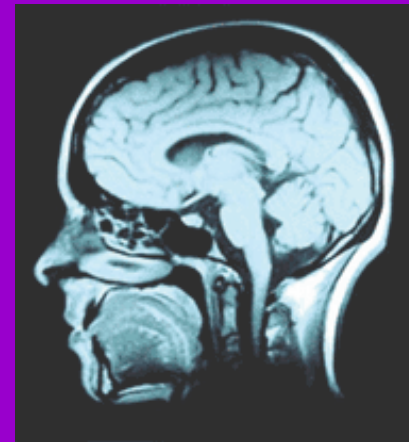
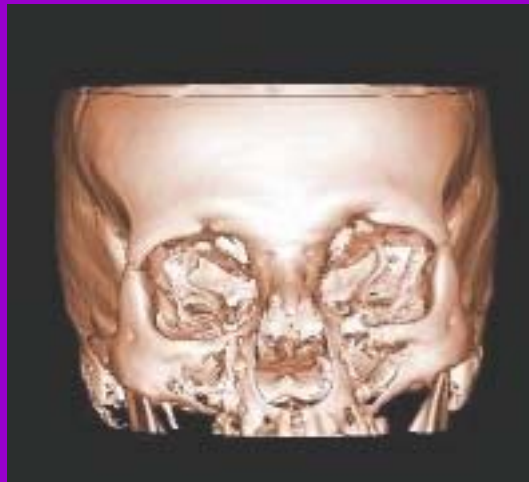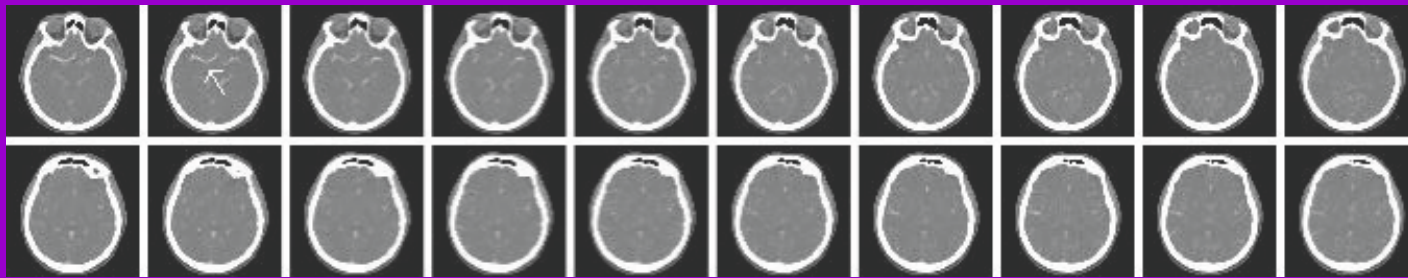
April, 2006

Angela Scheuerle, M.D.

Head

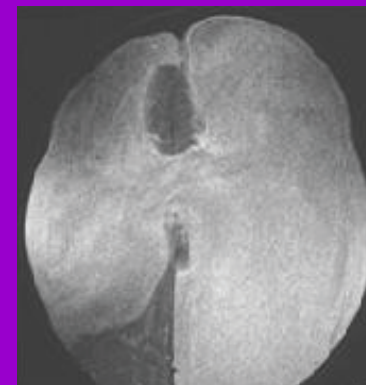
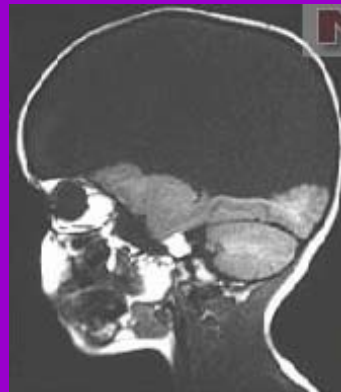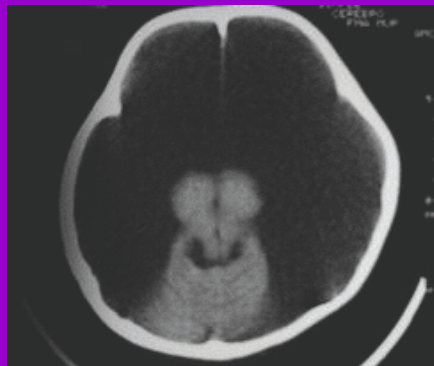
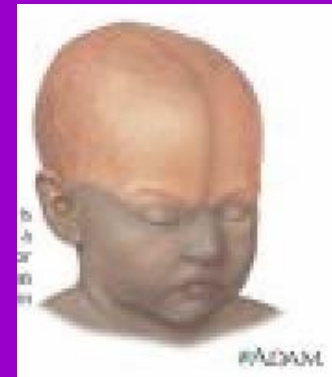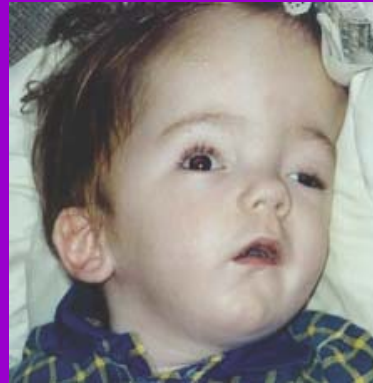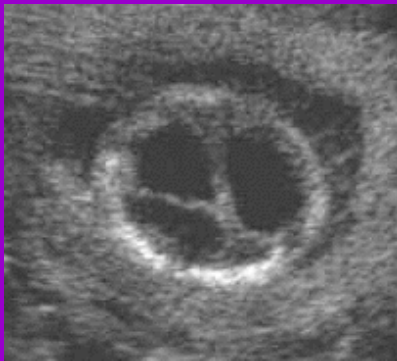
TACATGAGGTTCCGCTAGACTAGCTACTCACTAGCTATGTCTCGGTYACGATCTATACGCCGGAGCTAGGCCTTATCTATCTTACTTCGAGCTATGGACTTCAGAAGAAGCTCAGACTAGCACGCTTATATTTTTTTTTT

CT and MRI



Head - Hydrancephaly

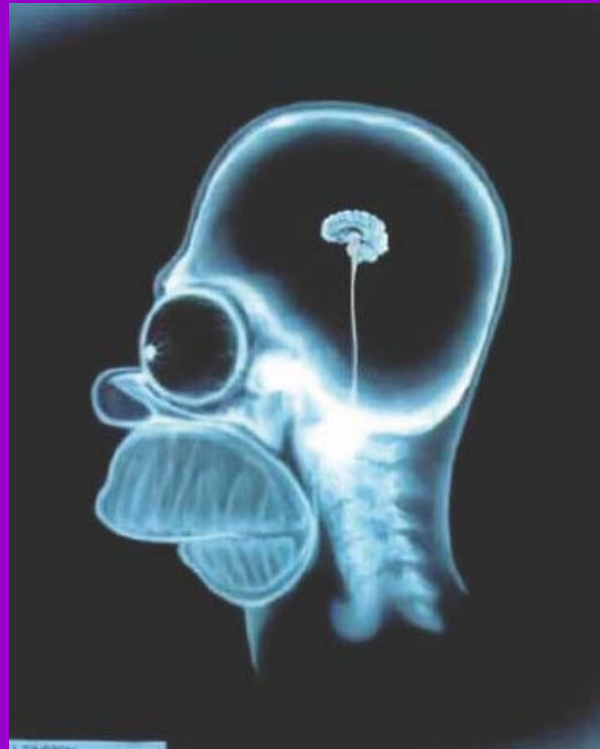
TACATGAGGTTCCGCTAGACTAGCTACTCACTAGCTATGTCTCGGTYACGATCTATACGCCGGAGCTAGGCCTTATCTATCTTACTTCGAGCTATGGACTTCAGAAGAAGCTCAGACTAGCACGCTTATATTTTTTTTTT



April, 2006

Angela Scheuerle, M.D.

TACATGAGGTTCCGCTAGACTAGCTACTCACTAGCTATGTCTCGGTYACGATCTATACGCCGGAGCTAGGCCTTATCTATCTTACTTCGAGCTATGGACTTCAGAAGAAGCTCAGACTAGCACGCTTATATTTTTTTTTT



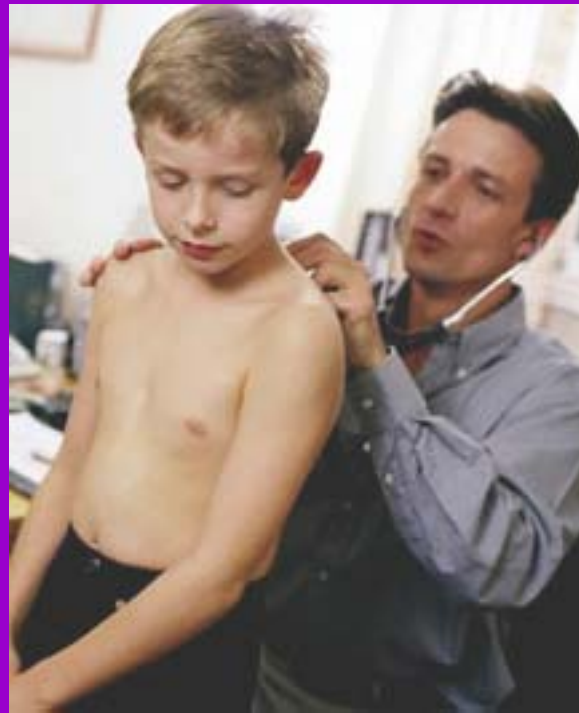April, 2006

Angela Scheuerle, M.D.

Chest

TACATGAGGTTCCGCTAGACTAGCTACTCACTAGCTATGTCTCGGTYACGATCTATACGCCGGAGCTAGGCCTTATCTATCTTACTTCGAGCTATGGACTTCAGAAGAAGCTCAGACTAGCACGCTTATATTTTTTTTTT

Physical Exam



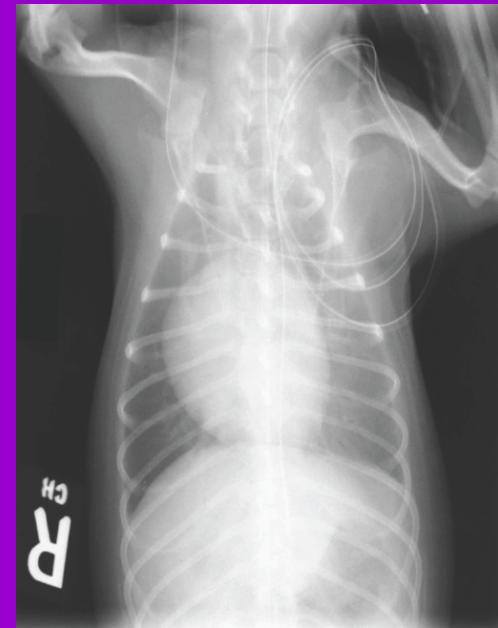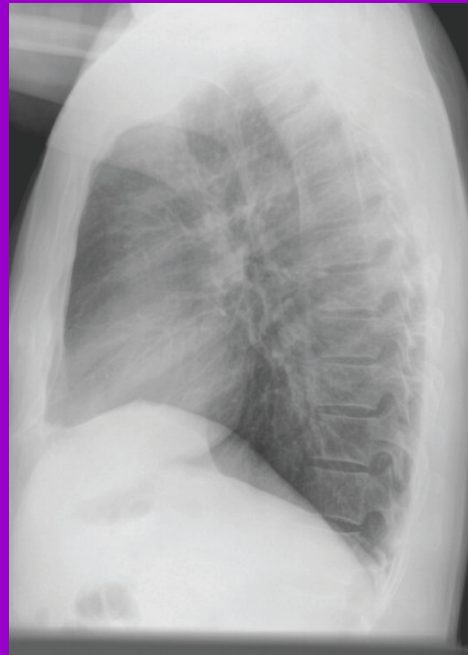
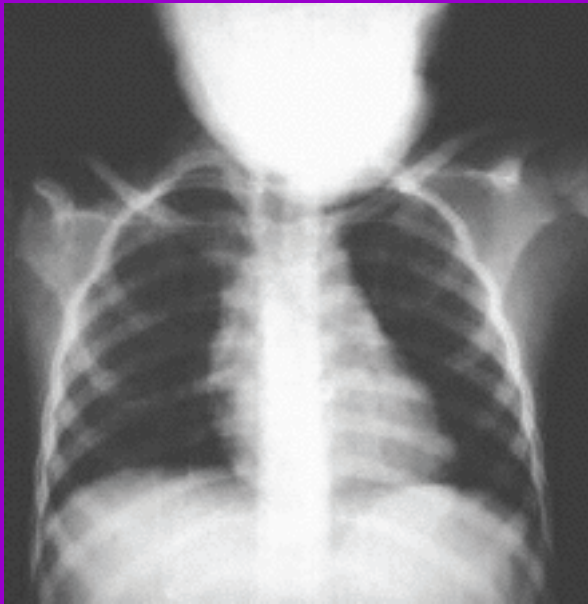
April, 2006

Angela Scheuerle, M.D.

Chest

TACATGAGGTTCCGCTAGACTAGCTACTCACTAGCTATGTCTCGGTYACGATCTATACGCCGAGCTAGGCCTTATCTATCTTACTTCGAGCTATGGACTTCAGAAGAAGCTCAGACTAGCACGCTTATATTTTTTTTTT

Xray



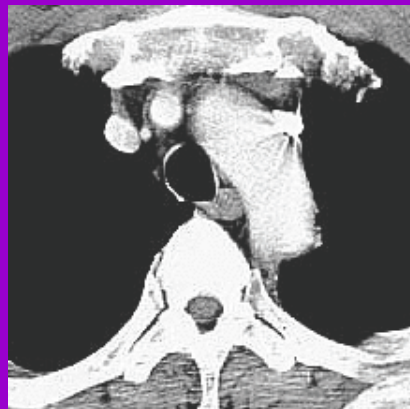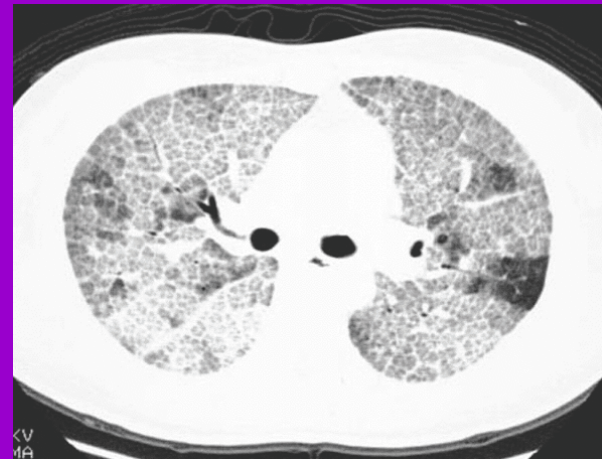
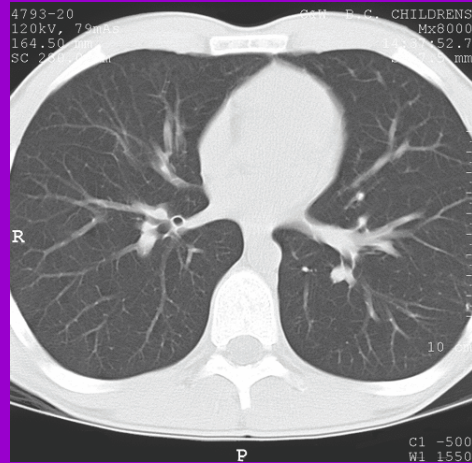April, 2006

Angela Scheuerle, M.D.

Chest

TACATGAGGTTCCGCTAGACTAGCTACTCACTAGCTATGTCTCGGTYACGATCTATACGCGGAGCTAGGCCTTATCTATCTTACTTCGAGCTATGGACTTCAGAAGAAGCTCAGACTAGCACGCTTATATTTTTTTTTT

CT and MRI

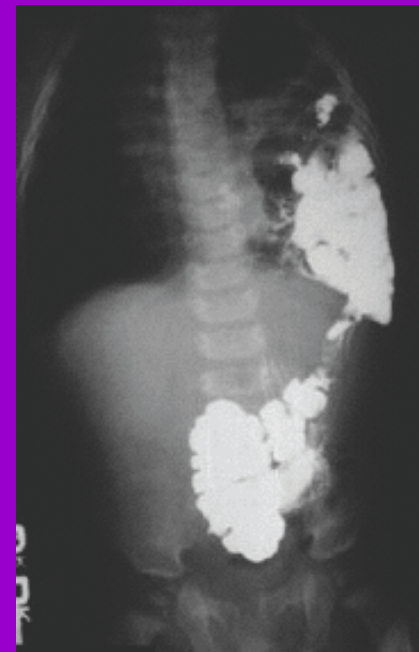
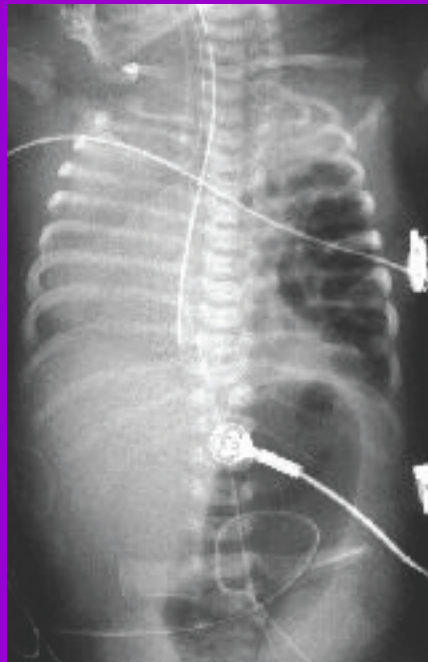
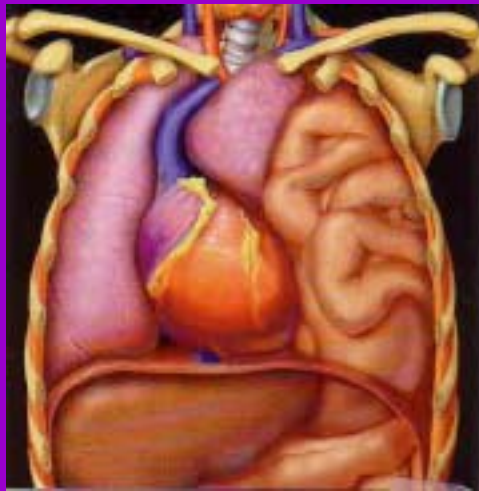

April, 2006

Angela Scheuerle, M.D.

Chest - Diaphragmatic Hernia

TACATGAGGTTCCGCTAGACTAGCTACTCACTAGCTATGTCTCGGTACGATCTATACGCCGGAGCTAGGCCTTATCTATCTTACTTCGAGCTATGGACTTCAGAAGAAGCTCAGACTAGCACGCTTATATTTTTTTTTT



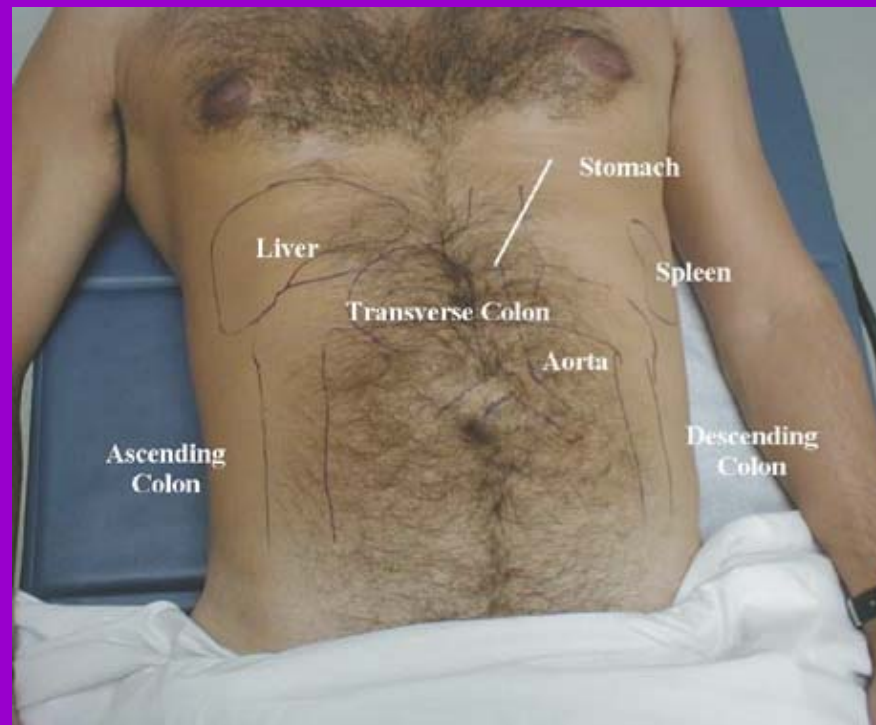
April, 2006

Angela Scheuerle, M.D.

Abdomen

TACATGAGGTTCCGCTAGACTAGCTACTCACTAGCTATGTCTCGGTYACGATCTATACGCGGAGCTAGGCCCTTATCTATCTTACTTCGAGCTATGGACTTCAGAAGAAGCTCAGACTAGCACGCTTATATTTTTTTTTT

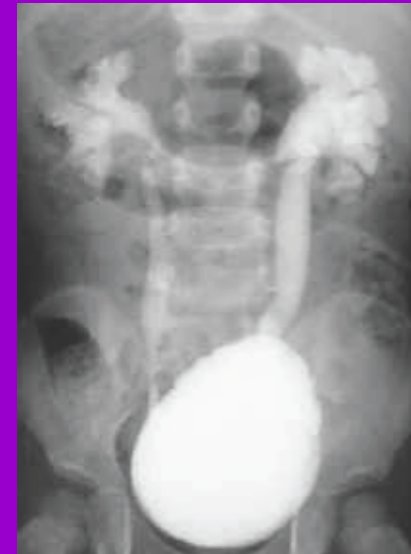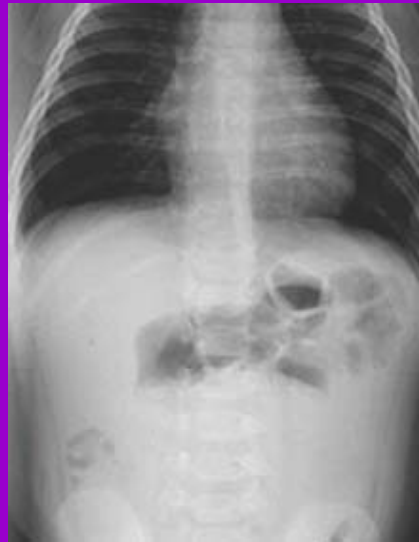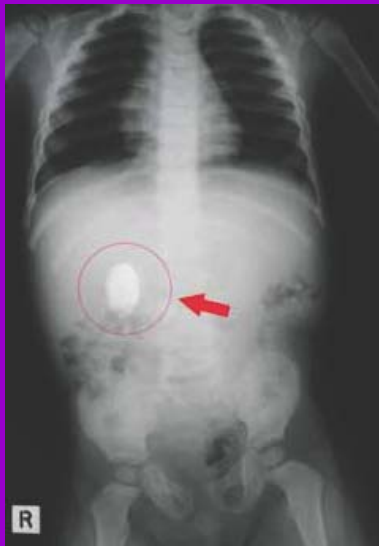Physical Exam



Abdomen

TACATGAGGTTCCGCTAGACTAGCTACTCACTAGCTATGTCTCGGTYACGATCTATACGCGGAGCTAGGCCTTATCTATCTTACTTCGAGCTATGGACTTCAGAAGAAGCTCAGACTAGCACGCTTATATTTTTTTTTT

Xray



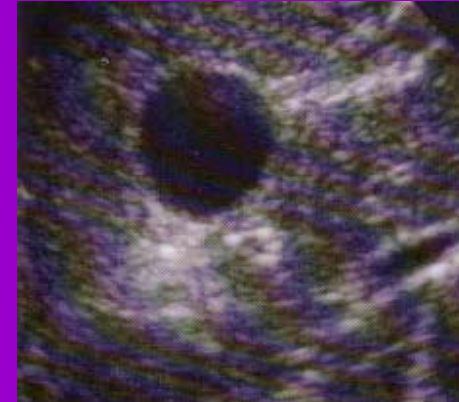
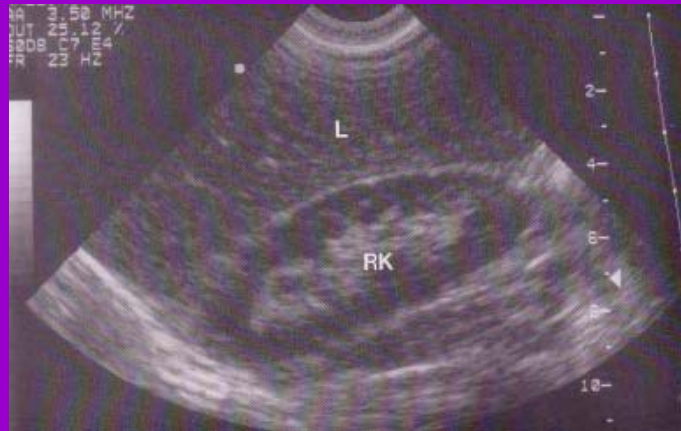April, 2006

Angela Scheuerle, M.D.

Abdomen

TACATGAGGTTCCGCTAGACTAGCTACTCACTAGCTATGTCTCGGTYACGATCTATACGCCGAGCTAGGCCTTATCTATCTTACTTCGAGCTATGGACTTCAGAAGAAGCTCAGACTAGCACGCTTATATTTTTTTTTT

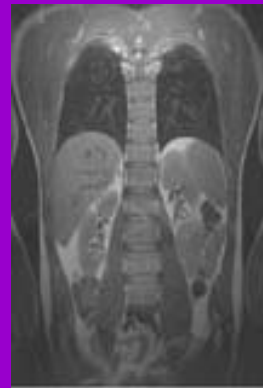
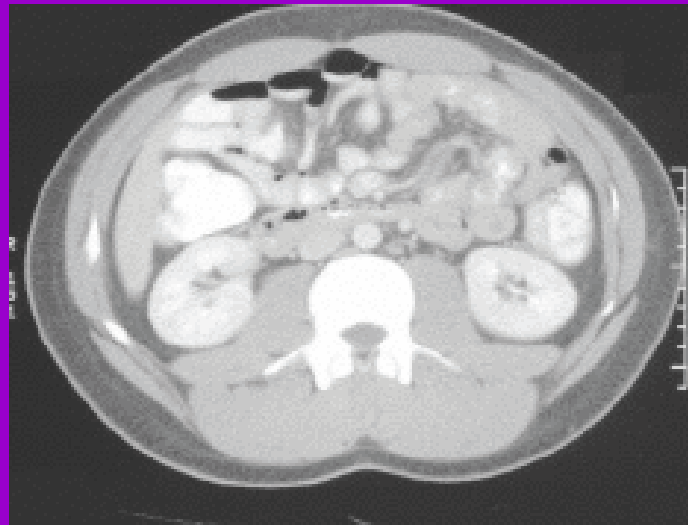
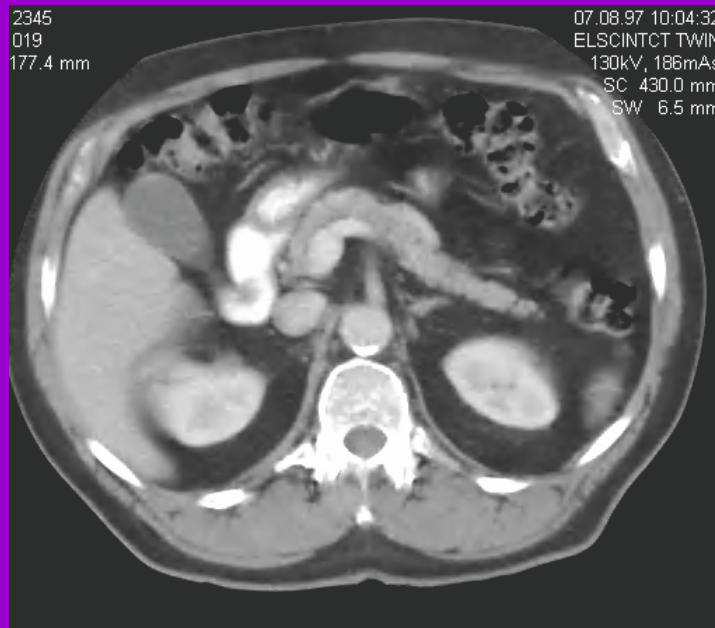
Ultrasound



Abdomen

TACATGAGGTTCCGCTAGACTAGCTACTCACTAGCTATGTCTCGGTYACGATCTATACGCCGGAGCTAGGCCCTTATCTATCTTACTTCGAGCTATGGACTTCAGAAGAAGCTCAGACTAGCACGCTTATATTTTTTTTTTT

CT and MRI

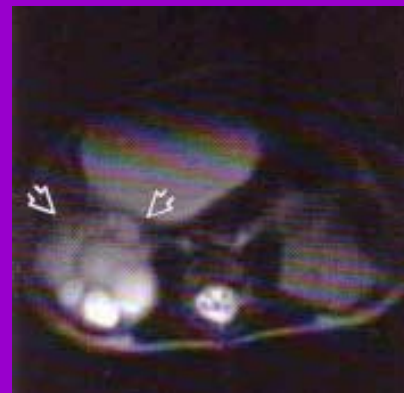
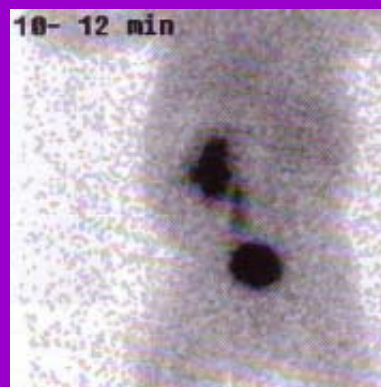
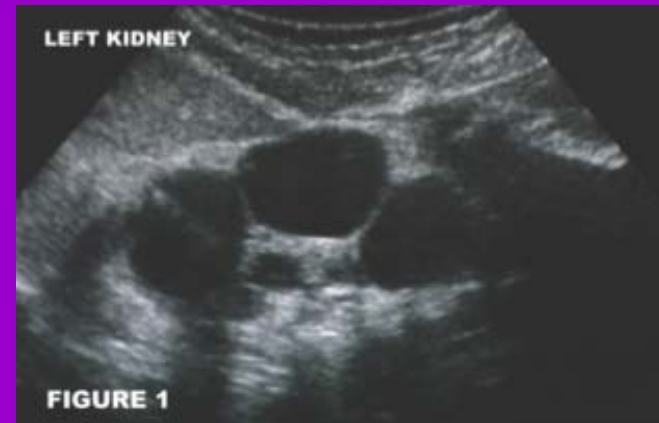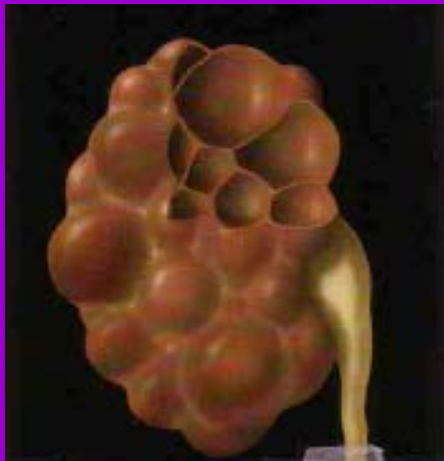


April, 2006

Angela Scheuerle, M.D.

Abdomen

TACATGAGGTTCCGCTAGACTAGCTACTCACTAGCTATGTCTCGGTYACGATCTATACGCCGAGCTAGGCCATTATCTATCTTACTTCGAGCTATGGACTTCAGAAGAAGCTCAGACTAGCACGCTTATATTTTTTTTTT



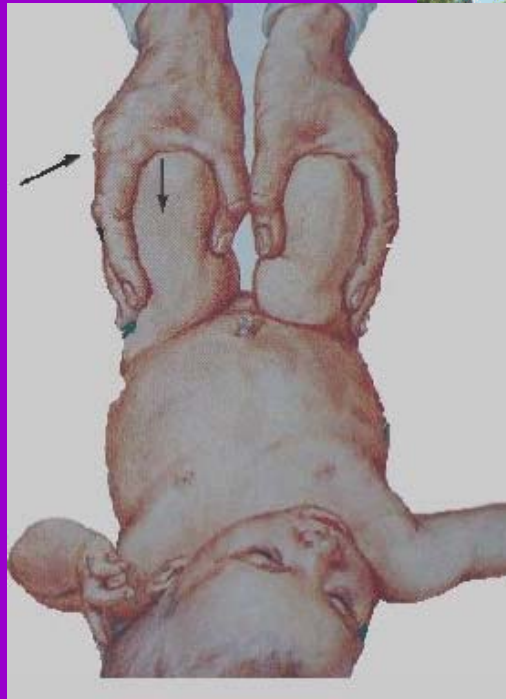
April, 2006

Angela Scheuerle, M.D.

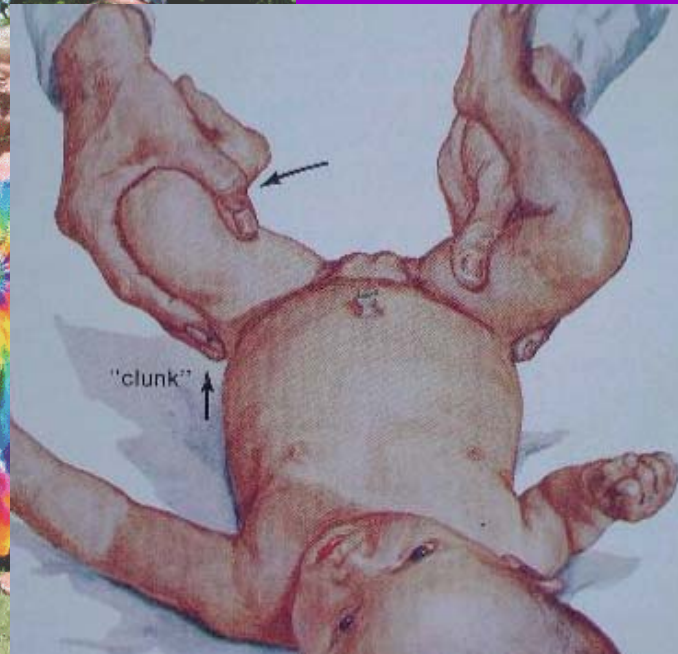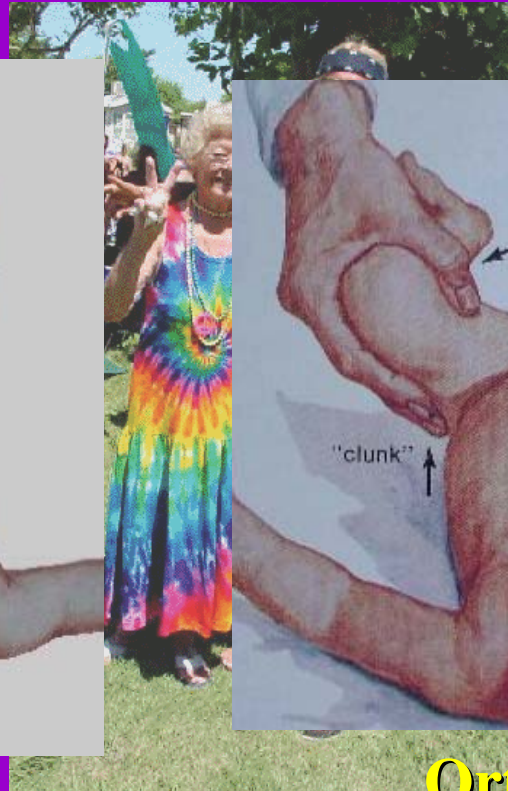Hip

TACATGAGGTTCCGCTAGACTAGCTACTCACTAGCTATGTCTCGGTYACGATCTATACGCCGGAGCTAGGCCTTATCTATCTTACTTCGAGCTATGGACTTCAGAAGAAGCTCAGACTAGCACGCTTATATTTTTTTTTT

Physical Exam



Barlow

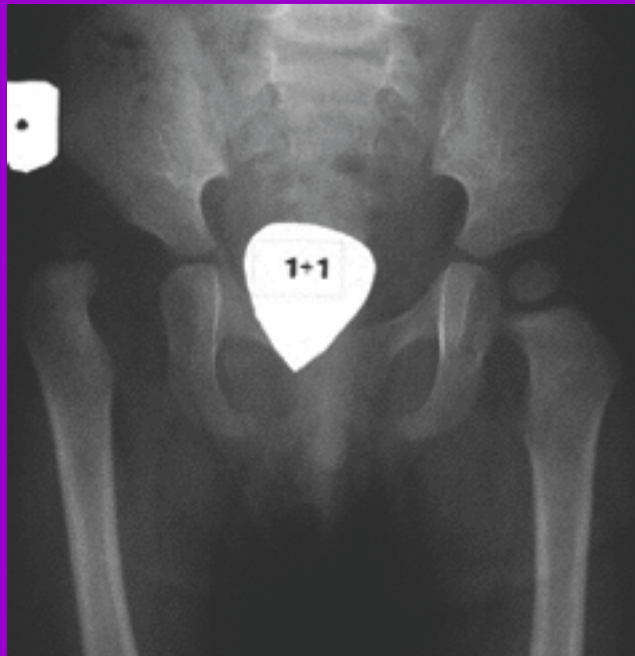


Ortolani

Hip

TACATGAGGTTCCGCTAGACTAGCTACTCACTAGCTATGTCTCGGTYACGATCTATACGCCGAGCTAGGCCTTATCTATCTTACTTCGAGCTATGGACTTCAGAAGAAGCTCAGACTAGCACGCTTATATTTTTTTTTT

Xray



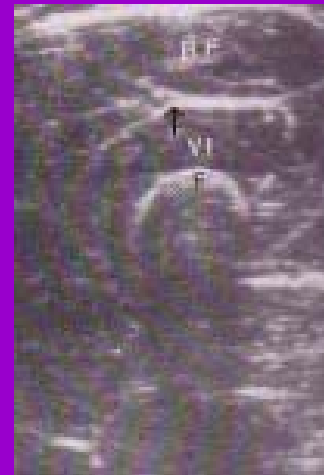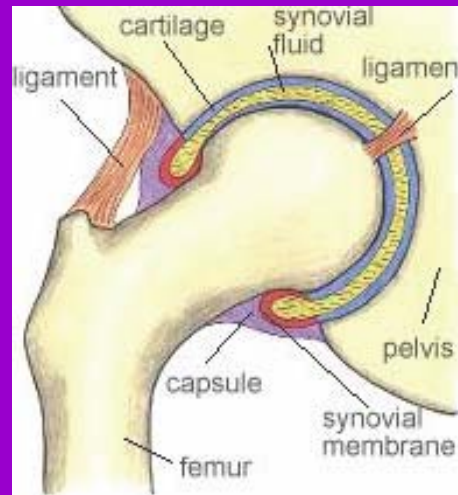
April, 2006

Angela Scheuerle, M.D.

Hip

TACATGAGGTTCCGCTAGACTAGCTACTCACTAGCTATGTCTCGGTYACGATCTATACGCGGAGCTAGGCCTTATCTATCTTACTTCGAGCTATGGACTTCAGAAGAAGCTCAGACTAGCACGCTTATATTTTTTTTTT

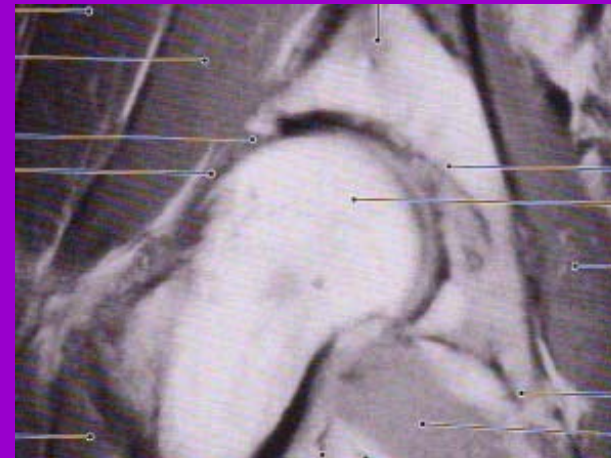
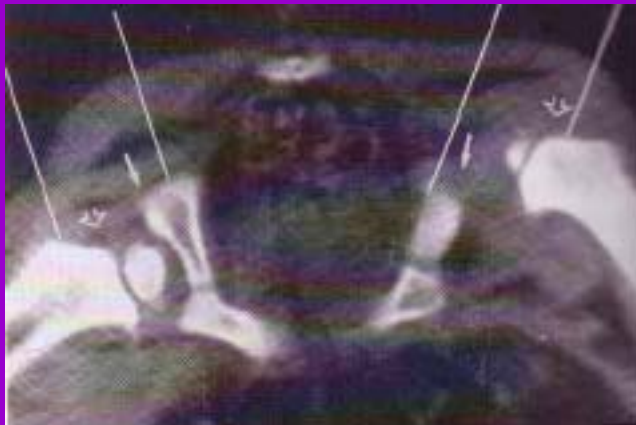
Ultrasound



Hip

TACATGAGGTTCCGCTAGACTAGCTACTCACTAGCTATGTCTCGGTYACGATCTATACGCCGGAGCTAGGCCTTATCTATCTTACTTCGAGCTATGGACTTCAGAAGAACTCAGACTAGCACGCTTATATTTTTTTTTT

CT and MRI



April, 2006

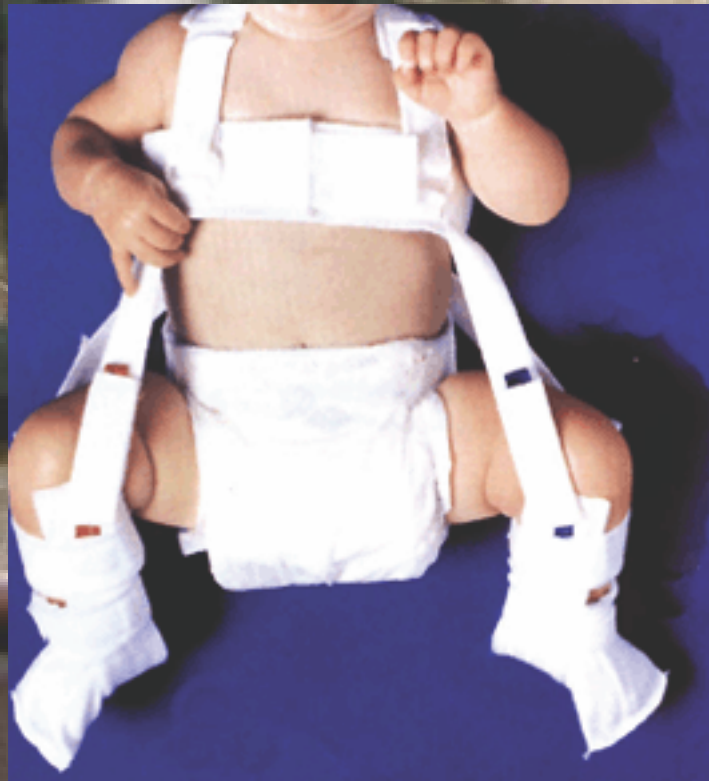Angela Scheuerle, M.D.

Hip

TACATGAGGTTCC

ATTTTTTTTTTT

Pavlik Harness



April, 2006

Angela Scheuerle, M.D.

TACATGAGGTTCCGCTAGACTAGCTACTCACTAGCTATGTCTCGGTYACGATCTATACGCGGAGCTAGGCCTTATCTATCTTACTTCGAGCTATGGACTTCAGAAGAAGCTCAGACTAGCACGCTTATATTTTTTTTTT



April, 2006

Angela Scheuerle, M.D.